

# Interactive CardioVascular and Thoracic Surgery

## **Thoracoscopic thymectomy with the 'da Vinci' surgical system in patient with myasthenia gravis**

Federico Rea, Luigi Bortolotti, Rodolfo Girardi and Francesco Sartori

*Interact CardioVasc Thorac Surg* 2003;2:70-72

DOI: 10.1016/S1569-9293(02)00104-4

The online version of this article, along with updated information and services, is  
located on the World Wide Web at:

<http://icvts.ctsnetjournals.org/cgi/content/full/2/1/70>

*Interactive Cardiovascular and Thoracic Surgery* is the official journal of the European Association for Cardio-thoracic Surgery (EACTS) and the European Society for Cardiovascular Surgery (ESCVS). Copyright © 2003 by European Association for Cardio-thoracic Surgery. Print ISSN: 1569-9293.

Case report – Thoracic general

# Thoracoscopic thymectomy with the ‘da Vinci’ surgical system in patient with myasthenia gravis

Federico Rea<sup>\*</sup>, Luigi Bortolotti, Rodolfo Girardi, Francesco Sartori

*Division of Thoracic Surgery, University of Padua, Via Giustiniani, 2, 35128 Padua, Italy*

Received 30 May 2002; received in revised form 22 October 2002; accepted 4 November 2002

## Abstract

We report a thoracoscopic thymectomy performed completely with a robotic surgical system: ‘da Vinci surgical system’, in a 23-year-old woman with myasthenia gravis.

© 2002 Elsevier Science B.V. All rights reserved.

**Keywords:** Myasthenia gravis (MG); Thymectomy; Technique; Robotic surgery

## 1. Introduction

Thymectomy is a widely accepted therapy for patients with myasthenia gravis (MG), but controversy persists regarding the indications and timing for operations.

Since Blalock et al. [1] first demonstrated the beneficial effect of thymectomy in 1939, the procedure has become increasingly accepted in the treatment of MG. However, the optimal selection of patients for surgery remains controversial.

Multiple techniques are described for removal of the thymus in MG: Transcervical T. (basic or extended), Video-Assisted T. (classic or extended), Transsternal (standard or extended), Infra-sternal mediastinoscopic T.

There is an ongoing debate about the most suitable surgical approach for thymectomy as illustrated by the wide variety of different techniques that have been described in the literature [2–6].

We describe a new thoracoscopic approach with a robotic surgical system, da Vinci surgical system, for thymectomy in a patient with MG.

## 2. Case report

In April 2002 a 23-year-old woman presenting MG with diplopia and generalized weakness (IIa Osserman and Genkins classification) was admitted to the Division of Thoracic Surgery of University of Padua.

The diagnostic procedures included chest radiograph,

thoracic computed tomography, assessment of pulmonary function and complete neurological work-up (serological testing, clinical staging according to the modified Besinger score, electromyography) to establish the stage of MG according to Ossermann.

Chest computed tomography (CT) was also important to exclude the possibility of thymoma (Fig. 1).

After achievement of adequate general and epidural anesthesia, the patient was placed in the 30° lateral decubitus position under single right-lung ventilation.

First, a small incision of 2 cm in length was made at the fifth intercostal space on the anterior portion of midaxillary region and was utilized to introduce the 3-dimensional stereoendoscope of the da Vinci system.

Two additional thoracic ports were inserted through the third intercostal space on the anterior portion of midaxillary region and the fifth intercostal space on midclavicular line (Fig. 2a).

Then two arms of the da Vinci system were attached to these two access points while another one was attached to the port-inserted endoscope.

For the left arm, an Endo Wrist instrument was used, and for the right arm an Endo-dissector device with electric cautery function was mainly used.

The left arm was mainly used to grasp the thymus and the right arm was used to perform the dissection.

The thymic gland, the anterior mediastinal and neck fat tissue was radically dissected and the specimen was brought into an Endo-Bag and could thus be removed through the trocar incision.

After the insertion of a 28 F drainage tube through the

<sup>\*</sup> Corresponding author. Tel.: +39-49-8212-237; fax: +39-49-8212-249.  
E-mail address: federico.rea@unipd.it (F. Rea).

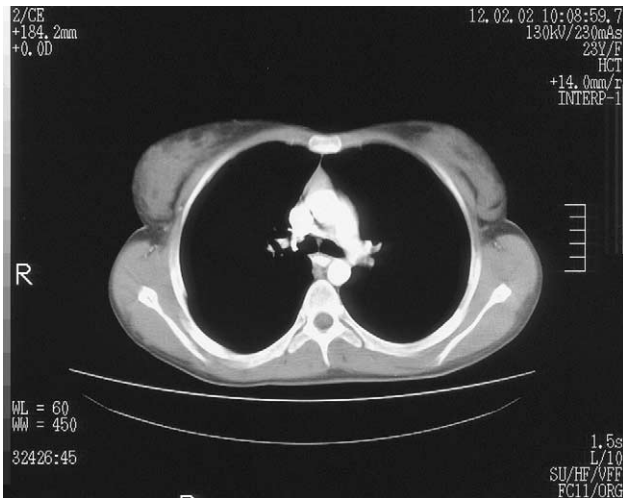

Fig. 1. CT scan shows thymic hyperplasia.

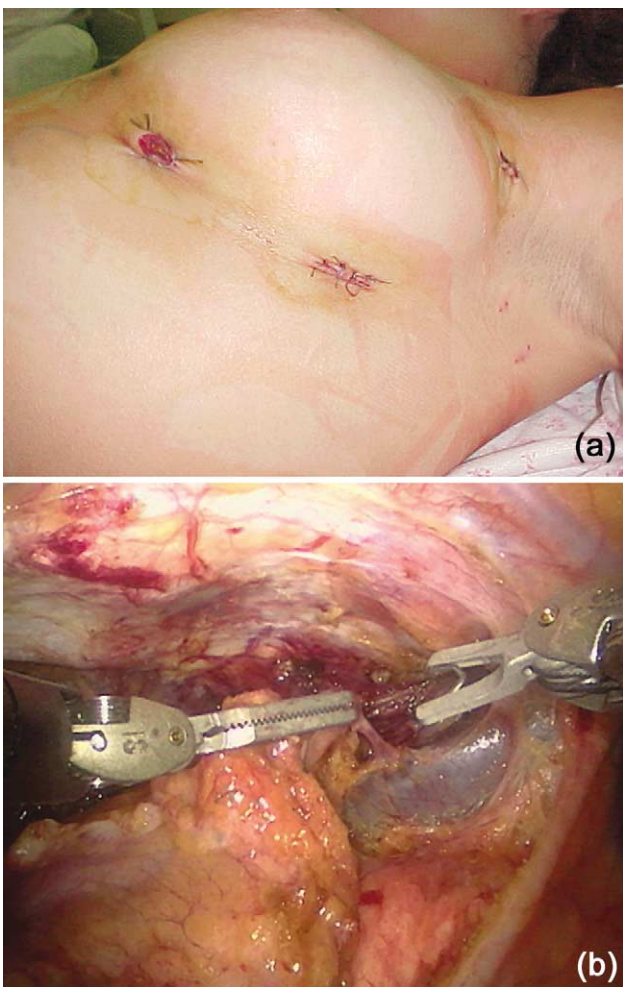


Fig. 2. (a) View illustrating the port entry sites. (b) Intraoperative view: the left anonymous vein is isolated and the thymic veins are clipped. A video clip of this figure can be viewed at <http://www.icvts.org/elan/Thymectomy.mpg>

wound of the fifth intercostal space, the other wounds were closed.

The total operative time was 1 h 20 min. The post-operative course was uneventful and the thoracic drain was removed on first day. The time of hospital stay was 2 days.

### 3. Discussion

Thymectomy is an accepted therapeutic option for treating MG. There are various conventional approaches for thymectomy with different degrees of invasiveness, reflecting the ongoing controversy over the best surgical approach for thymectomy in myasthenic patients. At our institution, the preferred conventional approach was formerly a transcervical thymectomy with or without a left videothoracoscopic approach.

Great progress has recently been made in the development of robotic surgical systems and after the first application in the field of coronary arterial bypass [7], now this systems start to be used for intrathoracic diseases [8]. So we believe that this new robotic operation may provide, at some time, a lesser degree of invasiveness, with a maximal radicality in thymectomy. With this robotic procedure we can clearly visualize the entire thymus and the mediastinal and neck fat tissue better than other conventional thoracoscopic operations. This robotic system enhances visualization of mediastinum with a 3-dimensional view so that we can perform a safer and easier dissection and ligation of thymic vessel (Fig. 2b).

In conclusion, we believe, that this robotic approach can enable the thoracic surgeon to perform a more radical and safer thymectomy than with conventional thoracoscopic operation with the same or even better cosmetic results.

### References

- [1] Blalock A, McGehee HA, Ford FR. The treatment of myasthenia gravis by removal of the thymus gland. *J Am Med Assoc* 1941;117:1529.
- [2] Jaretski III A. 'Maximal' thymectomy for myasthenia gravis. Surgical anatomy and operative technique. *J Thorac Cardiovasc Surg* 1988;96:711–716.
- [3] Maggi G, Casadio C, Cavallo A. Thymectomy in MG: results of 662 cases operated upon 15 years. *Eur J Cardiothorac Surg* 1989;3:504–511.
- [4] Yim APC, Kay LC, Izzat MB. Video-assisted thoracoscopic thymectomy for myasthenia gravis. *Semin Thorac Cardiovasc Surg* 1999;11:65–73.
- [5] Yim APC, Izzat MB. VATS approach to the thymus. In: Yim APC, Hazelrigg SR, Izzat MB, Landreneau RJ, Mack MJ, Naunheim KS, editors. *Minimal access cardiothoracic surgery*, Philadelphia, PA: WB Saunders Company, 2000. pp. 209–220.
- [6] Uchiyama A, Shuji S, Hiroyuki H. Infrasternal mediastinoscopic thymectomy in myasthenia gravis: surgical results in 23 patients. *Ann Thorac Surg* 2001;72:1902–1905.
- [7] Loumet D, Carpentier A, D'Attellis N, Berrebi A, Cardon C, Ponzio O. Endoscopic coronary artery bypass grafting with the aid of robotic assisted instruments. *J Thorac Cardiovasc Surg* 1999;118:4–10.
- [8] Yoshino I, Hashizume M, Shimada M, Tomikawa M, Tomiyasu M, Suemitsu R, Sugimachi K. Thoracoscopic thymectomy with the da

Vinci computer-enhanced surgical system. *J Thorac Cardiovasc Surg* 2001;122:783–785.

## **Appendix A. Disclaimer**

Neither the authors, nor the publisher nor the European Association for Cardiothoracic Surgery warrant that the data

files are free of defects, or that the documentation is accurate. Neither the authors, nor the publisher nor the European Association for Cardiothoracic Surgery are liable for any damage of whatever kind sustained through downloading and/or using the files. By downloading and/or using the files, the reader, acting as user of an electronic publication, agrees to the above terms and conditions.

**Thoracoscopic thymectomy with the 'da Vinci' surgical system in patient with myasthenia gravis**

Federico Rea, Luigi Bortolotti, Rodolfo Girardi and Francesco Sartori

*Interact CardioVasc Thorac Surg* 2003;2:70-72

DOI: 10.1016/S1569-9293(02)00104-4

**This information is current as of October 18, 2011**

<b>Updated Information &amp; Services</b>	including high-resolution figures, can be found at: <a href="http://icvts.ctsnetjournals.org/cgi/content/full/2/1/70">http://icvts.ctsnetjournals.org/cgi/content/full/2/1/70</a>
<b>Supplementary Material</b>	Supplementary material can be found at: <a href="http://icvts.ctsnetjournals.org/cgi/content/full/2/1/70/DC1">http://icvts.ctsnetjournals.org/cgi/content/full/2/1/70/DC1</a>
<b>References</b>	This article cites 7 articles, 6 of which you can access for free at: <a href="http://icvts.ctsnetjournals.org/cgi/content/full/2/1/70#BIBL">http://icvts.ctsnetjournals.org/cgi/content/full/2/1/70#BIBL</a>
<b>Citations</b>	This article has been cited by 4 HighWire-hosted articles: <a href="http://icvts.ctsnetjournals.org/cgi/content/full/2/1/70#otherarticles">http://icvts.ctsnetjournals.org/cgi/content/full/2/1/70#otherarticles</a>
<b>Subspecialty Collections</b>	This article, along with others on similar topics, appears in the following collection(s): <b>Mediastinum</b> <a href="http://icvts.ctsnetjournals.org/cgi/collection/mediastinum">http://icvts.ctsnetjournals.org/cgi/collection/mediastinum</a> <b>Minimally invasive surgery</b> <a href="http://icvts.ctsnetjournals.org/cgi/collection/minimally_invasive_surgery">http://icvts.ctsnetjournals.org/cgi/collection/minimally_invasive_surgery</a>
<b>Permissions &amp; Licensing</b>	Requests to reproducing this article in parts (figures, tables) or in its entirety should be submitted to: <a href="mailto:icvts@ejcts.ch">icvts@ejcts.ch</a>
<b>Reprints</b>	For information about ordering reprints, please email: <a href="mailto:icvts@ejcts.ch">icvts@ejcts.ch</a>

# Interactive CardioVascular and Thoracic Surgery